

Chiari I Malformation Detectable Only by the Upright™ MRI Leads to Successful Surgery



J.P. Elsig, M.D.
Orthopedic Surgeon,
Fellow of the Swiss Orthopedic Society,
Member of the Board of the Swiss Spine Society,
FMRI Zentrum - Zurich,
Switzerland

More Proof: Case Study #4

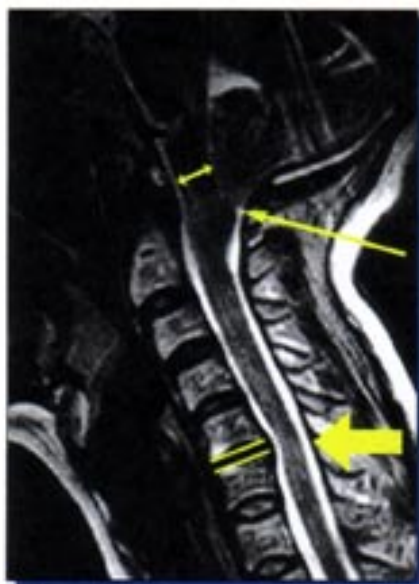Clinical Case Overview

A 50-year-old woman had been suffering for years from neck pain. A prior recumbent MRI had shown a C5-6 disc degeneration with a posterior bulge and a moderate segmental kyphosis.

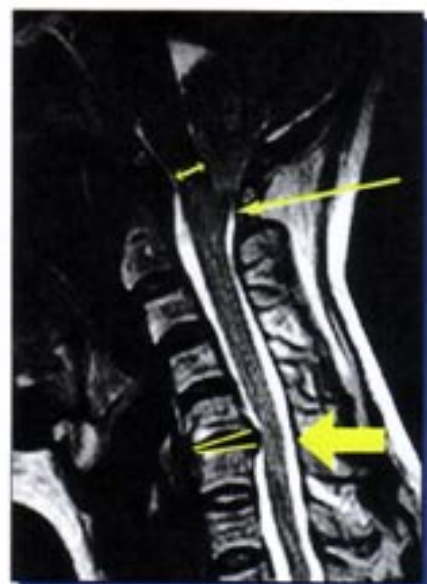
Despite repeated attempts with conservative treatment, the patient's symptoms worsened and were marked by the onset of transient paresthesia, transient loss of muscle tone in the legs and drop attacks.

When the Upright™ MRI was performed, it showed both an increased disc protrusion and segmental kyphosis at C5-6 relative to the recumbent MRI (thick arrow), as well as a descent of the cerebellar tonsils behind the arch of C1 (thin arrow) accompanied by brainstem compression (double arrow) against the odontoid process.


This Chiari I Malformation, with position-related downward herniation through the foramen magnum visible only by means of the FONAR Upright™ MRI, explained the drop attacks and the transient loss of tone in the legs, which could not be accounted for by only the C5-6 bulge seen on the recumbent MRI.



Recumbent



Upright



FONAR Multi-Position™ Upright™ MRI

With the achievement of the correct diagnosis of the patient's symptoms, made possible by the FONAR Upright™ MRI, the correct surgical treatment was accomplished and consisted of a posterior fossa decompression plus a C1 laminectomy with dural plasty. The C5-6 herniation and kyphosis that was aggravated by the upright position is presently treated conservatively, as the patient is not yet ready for another surgery.



Scheduling: 615.620.5480 • Fax: 615.321.0509

1718 Charlotte Avenue, Suite B, Nashville, TN 37066
www.nextgenerationimaging.com