

Reducing Failed Back Surgery

More Proof: Case History #2

A 57-year old woman presented with pain of one year's duration following failed back surgery performed in 2001.*

The patient continued to experience persistent low back-pain, accompanied by sensations of coldness and numbness in both thighs and legs. The patient often required mechanical support to stabilize her walking.

During the year following surgery, the patient sought help from multiple medical specialists. She provided her recumbent MRI images to them. She was told the images showed nothing that could account for her symptoms and that nothing more could be done. Her surgeon rejected the prospect of additional surgery. A Florida neurologist suggested to her that her problem was "in her head."

The imaging center that evaluated her recommended she be scanned in an Upright™ MRI due to the possibility that an Upright scan, unlike the conventional recumbent scan, is weight-bearing and "might uncover something." Her family physician wrote the prescription, and the patient drove from her home in the Florida panhandle to the closest FONAR Upright MRI center, which at the time was in Tampa over 425 miles away.

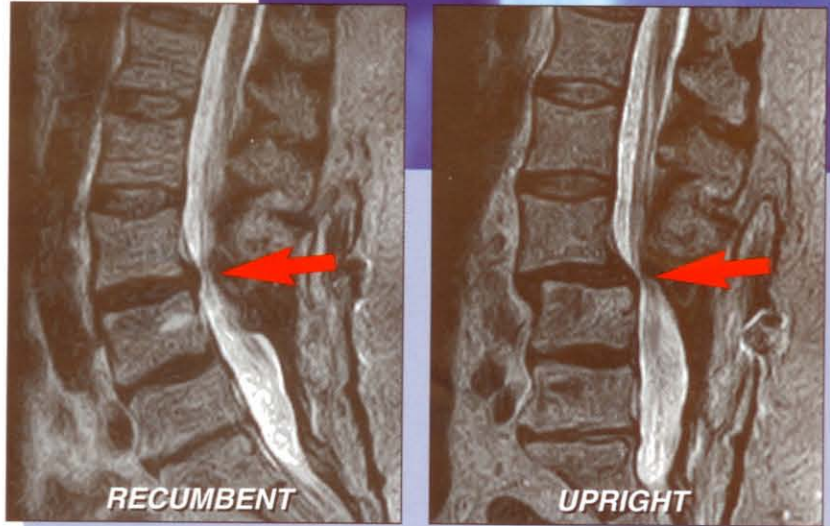
The patient was scanned in the patented FONAR Upright MRI in early 2002, one year after her spinal fusion. Both Upright and recumbent scans were performed on her in the multi-position FONAR Upright MRI.

The recumbent MRI (left image) exhibited only a normal lumbar lordotic curve and a modest bulge of the L3-4 intervertebral disc, consistent with her prior recumbent MRI scans. The FONAR Upright scan (right image) revealed, however, a marked position-dependent subluxation (anterolisthesis) at L3-4 and an accompanying spinal stenosis that were not visible on the recumbent MRI.

The patient's Upright images established that there was a genuine physical basis for her symptoms, whereas her recumbent MRI images had failed to do so. The new Upright images supplied her surgeon with the necessary evidence that additional surgery was warranted to correct her problem.

A spinal fusion was performed at L3-4 one month after the patient's Upright MRI scan. The surgical outcome was positive. To date, almost four years post-op, the patient remains symptom free and reported to FONAR, "Thank you for giving me my life back."

* laminectomy and L4S1 fusion



same patient...same scanner...same day

(Images courtesy of M. Rose, MD; Rose Radiology Centers)

TV Dramatization of Actual Case History



FONAR UPRIGHT™ MRI

"Thank you for giving me my life back."



Scheduling: 615.620.5480 • Fax: 615.321.0509

4749 Charlotte Avenue, #D, Nashville, TN 37209